were ten deaths from sepsis after vaginal delivery and five were due to group A streptococcal infection. One of these women had a hysterectomy, and the specimen showed extensive haemorrhagic infarction; another woman died before onset of labour[9]. The common feature of all these cases, including ours, was insidious onset with rapid progress to septicaemia. Our report emphasizes the recommendations of the *Report on Confidential Enquiries* that puerperal sepsis is not a disease of the past and all health care professionals must be aware of this aggressive illness.

REFERENCES

1 Massel BF, Chutte CG, Walker AM, Kurland GS. Penicillin and the marked decrease in morbidity and mortality from rheumatic fever in the United States. *N Engl J Med* 1988;**318**:280–6

2 Quinn RW. Epidemiology of group A streptococcal infections—their changing frequency and severity. *Yale J Biol Med* 1982;**55**:265–70

3 Nathan L, Peters MT, Ahmed AM, Leveno KJ. The return of life-threatening puerperal sepsis caused by group A streptococci. *Am J Obstet Gynecol* 1993;**169**:571–2

4 Silver RM, Heddleston LN, McGregor JA, Gibbs RS. Life-threatening puerperal infection due to group A streptococci. *Obstet Gynecol* 1992;**79**:894–6

5 Noronha S, Yue CT, Sekosan M. Puerperal group A beta haemolytic streptococcal toxic shock-like syndrome. *Obstet Gynecol* 1996;**88**:728

6 Martin PR, Hoiby EA. Streptococcal serogroup an epidemic in Norway 1987–1998. *Scand J Infect Dis* 1990;**22**:421–9

7 Holm SE. Invasive group A streptococcal infections. *N Engl J Med* 1996;**335**:590–1

8 Acharya U, Lamont CAR, Cooper K. Group A beta-haemolytic streptococcus causing disseminated intravascular coagulation and maternal death. *Lancet* 1988;**i**:595

9 UK Health Departments. *Report on Confidential Enquiries into Maternal Deaths in the United Kingdom 1994–1996*. London: HMSO, 1998

Ectopic pregnancies in two consecutive menstrual cycles

Laurie Montgomery Irvine MD MRCOG
David Glyn Evans MBE FRCOG[1]
Marcus Edward Setchell FRCS FRCOG[2]

J R Soc Med 1999;**92**:413–414

A woman who has had an ectopic pregnancy is at excess risk of another. In a study of 347 cases of ectopic pregnancy, the repeat ectopic rate was 11.2% with a mean interval of 2.83 years[1]. However, in a small study of patients treated conservatively, the recurrence rate was only 5%[2].

CASE HISTORY

A 28-year-old multigravid woman reported six weeks of amenorrhoea and two days of abdominal pain and vaginal bleeding. On examination she was haemodynamically stable; the abdomen was tender, and the uterus was bulky with tenderness in the left fornix. A urinary pregnancy test was positive. At laparotomy a small leaking left distal ectopic pregnancy was seen and a left partial salpingectomy was performed; the right adnexa was noted to be normal. She recovered uneventfully and was discharged home on the fifth postoperative day.

Watford General Hospital, Vicarage Road, Watford WD1 8HB; [1]21 Devonshire Place, London W1N 1PD; [2]Homerton Hospital, London E9, UK

Correspondence to: Mr L M Irvine, Consultant Obstetrician and Gynaecologist, Watford General Hospital, Vicarage Road, Watford, Herts WD1 8HB

At her eight-week follow-up visit she complained of right-sided abdominal pain, and on vaginal examination she was tender in the right adnexa. On admission the differential diagnosis was judged to be pelvic inflammatory disease, urinary tract infection or appendicitis. A transabdominal scan showed a normal-sized uterus with a 2 cm ill-defined echo-poor area by the right ovary, thought to be a small collection of fluid. She was afebrile and clinically stable. Treatment was started with intravenous erythromycin 200 mg three times daily and blood samples were taken six days apart for measurement of beta human chorionic gonadotropin, which was 120 U/L rising to 170 U/L. Her abdominal pain settled and she was clinically well; but, in the absence of a definitive diagnosis, another laparoscopy was done on day seven. She had a haemoperitoneum of 200 mL and a right distal leaking ectopic pregnancy. A right partial salpingectomy was performed. Histological examination of both fallopian tubes revealed chorionic villi, confirming the ectopic pregnancies. There was fusion of the plicae in the left tube, consistent with chronic salpingitis, although she gave no history of such disease.

COMMENT

This seems to be the first reported case of ectopic pregnancies in two consecutive menstrual cycles. Because of the great rarity of this event, we did not initially consider the possibility.

Risk factors for ectopic pregnancy include pelvic inflammatory disease, the use of intrauterine contraceptive devices, sexually transmitted diseases[3] and previous appendicectomy[4]. It is noteworthy that, although the patient gave no history of pelvic inflammatory disease, the

left fallopian tube showed evidence of such infection, with fusion of the plicae.

This case was from the Homerton Hospital, where we have previously reported one of the world's highest ectopic pregnancy rates[5]—2.62 ectopic pregnancies per 100 deliveries. Ectopic pregnancy is a major cause of maternal mortality, accounting in the UK for 19 deaths in the triennium 1988–1990. 15 were due to rupture. In 7 of the 15 cases, substandard care was identified. The 1994–96 *Confidential Enquiry into Maternal Deaths* emphasized that the diagnosis should be considered in any woman of reproductive age with lower abdominal pain, particularly of sudden onset[6]. This applies especially to women who have already had one ectopic pregnancy. If there is doubt, the patient should be followed by serial beta hCG measurements and ultrasound scans. If there is still doubt, a second laparoscopy should be considered. With the incidence of ectopic pregnancy increasing, bizarre cases (for example, heterotopic, bilateral or consecutive) will be seen more often.

Acknowledgments We thank Dr D Lowe, consultant histopathologist at St Bartholomew's Hospital, London, for help.

REFERENCES

1 Schoen JA, Nowok RJ. Repeat ectopic pregnancy: a 16 year clinical survey. *Obstet Gynecol* 1975;**45**:542–6

2 Zohar E, Geurer O, Segal S. Reproductive outcome after expectant management of ectopic pregnancy. *Eur J Obstet Gynaecol Reprod Biol* 1996;**66**:1–2

3 Sweet RL, Gibbs RS. *Diseases of the Female Genital Tract.* Baltimore: Williams & Wilkins, 1985:53–77

4 Johansen HM, Becker-Cristiansen F. Ectopic pregnancy in Greenland, an epidemiological study. *Arctic Med Res* 1990;**43**:43–7

5 Irvine LM, Hicks JL, Blair-Bell C, Setchell ME. The incidence of ectopic pregnancy in the City and Hackney Health District of London 1990–1991. *J Obstet Gynaecol* 1994;**14**:29–34

6 Why women die. *Report on Confidential Enquiries into Maternal Deaths in the United Kingdom 1988–1990.* London: HMSO, 1994:61–7

Selective embolization of bleeding renal angiomyolipoma in pregnancy

J Shah MB BSc J Jones MBBS
M A W Miller MD FRCS(Urol) U Patel MRCP FRCR
K M Anson MS FRCS(Urol)

J R Soc Med 1999;**92**:414–415

When a renal angiomyolipoma bleeds in pregnancy, the usual treatment is nephrectomy[1].

CASE HISTORY

A 36-year-old woman reported frank haematuria at 26 weeks' gestation. 2 years earlier she had had an uncomplicated full-term pregnancy. Renal ultrasound showed a 5 × 5 cm right upper pole renal mass compatible with a bleeding angiomyolipoma (Figure 1) but the bleeding settled spontaneously. She was readmitted at 28 weeks' gestation with further haematuria and right ureteric colic. Selective right renal arteriography revealed what appeared to be a large bleeding angiomyolipoma and this was successfully devascularized by means of polyvinyl alcohol particles (Figure 2). Radiation exposure was limited by careful coning of the uterus, sparing use of fluoroscopy and monitoring with a thermoluminescent dosimetry device. The haematuria settled immediately and she had an uncomplicated full-term delivery. On postpartum imaging there was a residual 1 cm fatty area within the right renal parenchyma, and she remains asymptomatic nine months later.

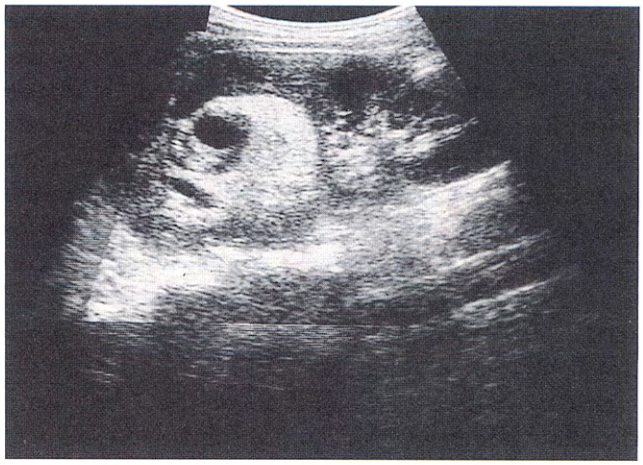

Figure 1 **Renal ultrasound appearance, first admission**

Department of Urology, St George's Hospital, London SW17 0QT, UK
Correspondence to: Mr K M Anson