

CASE REPORT

Serial serum HCG measurements in a patient with an ectopic pregnancy: a case for caution

Laurie Montgomery Irvine¹ and Malcolm L.Padwick

Consultant Gynaecologists, Department of Obstetrics and Gynaecology, Watford General Hospital, Vicarage Road, Watford, Herts WD1 8HB, UK

¹To whom correspondence should be addressed

Improvements in the use of ultrasound in early pregnancy have resulted in improved diagnosis of miscarriage and ectopic pregnancy. There are still, however, a significant number of women with a suspected abnormal pregnancy, where transvaginal ultrasound is unable to locate the pregnancy. The concern is the possibility of ectopic pregnancy. An alternative diagnostic tool is required and it has been suggested that it is possible to monitor serum β human chorionic gonadotrophin. The present case highlights the potential dangers of this management.

Key words: ectopic pregnancy/serial serum β HCG measurements/tubal rupture

Introduction

The clinical picture of ectopic pregnancy is changing. This is secondary to an increased awareness of the physician and improvements in ultrasound diagnosis of ectopic pregnancies (Cacciatori *et al.*, 1989). The result is a reduction in ruptured ectopic pregnancy at presentation. Transvaginal ultrasound has become the first line diagnostic tool for the assessment of early pregnancy disorders. There are still, however, a significant proportion of women with suspected early pregnancy abnormality, positive urine pregnancy test and an ultrasound scan which is unable to identify the location of pregnancy (Cacciatori *et al.*, 1988; Hahlin *et al.*, 1995; Banerjee *et al.*, 1999). In such cases an alternate diagnostic modality is required. The two main options proposed are diagnostic surgical laparoscopy (Ankum *et al.*, 1993) or quantification of pregnancy hormones such as serum beta human chorionic gonadotrophin (β HCG) and progesterone (Kadar and Romero, 1988; Lindblom *et al.*, 1989; Stovall and Ling, 1993). It has recently been proposed that when ultrasound is unable to identify the pregnancy location and there is no evidence of haemoperitoneum, minimal discomfort and bleeding may be managed expectantly and monitored by serial changes in the serum concentration β HCG (Hahlin *et al.*, 1995; Banerjee *et al.*, 1999). The case presented highlights the potential problems in such management.

Case report

A 30 year old multigravid patient presented with a history of 6 weeks amenorrhoea and a 2 day history of light vaginal bleeding without pain. She had a positive urine pregnancy test. She had had a successful pregnancy 1 year earlier delivered by Caesarean section for fetal distress, and had had appendectomy aged 5 years. On examination the patient was stable and on palpation of the abdomen there was no tenderness or peritonism. Speculum examination revealed a closed cervix with no evidence of vaginal bleeding. The uterus was anteverted, enlarged and compatible with the menstrual history, with no adnexal tenderness. A transvaginal scan was unable to identify an intrauterine or extrauterine pregnancy. A right corpus luteal cyst of 8 mm diameter was seen and no free fluid was reported. The provisional diagnosis of a complete spontaneous abortion was made, although ectopic pregnancy was not excluded. She was managed as an outpatient and was seen on the gynaecology ward on six occasions over a 19 day period for serial serum β HCG measurements. The first β HCG concentration was recorded as 2367 IU/ml. The recorded values fell steadily and 19 days after first presenting the value was 97 IU/ml (Figure 1). At no time during her ward visits did she complain of abdominal tenderness or vaginal bleeding. Less than 12 h after last being seen she was admitted to the gynaecology ward with severe lower abdominal pain and vaginal bleeding. On examination she was not shocked but had a distended abdomen with guarding, and rebound tenderness. She was admitted and underwent a laparoscopy proceeding to laparotomy. At laparoscopy haemoperitoneum was diagnosed and at laparotomy a ruptured ectopic pregnancy was discovered at the isthmus of the left Fallopian tube. There was approximately one litre of fresh blood in the abdomen. The right Fallopian tube was noted to be buried in adhesions. A left partial salpingectomy was performed and the patient had an uneventful post-operative recovery and was discharged home after 4 days. Histological assessment of the surgical specimen confirmed an ectopic pregnancy.

Discussion

Ectopic pregnancy is a significant cause of maternal death in the UK, accounting for 12 deaths in the last confidential enquiry into maternal deaths 1994–1996 'Why mothers die' (Confidential enquiry into maternal deaths, 1999). Of these, eight deaths were considered to have received substandard care. This was most often due to delay in making the diagnosis

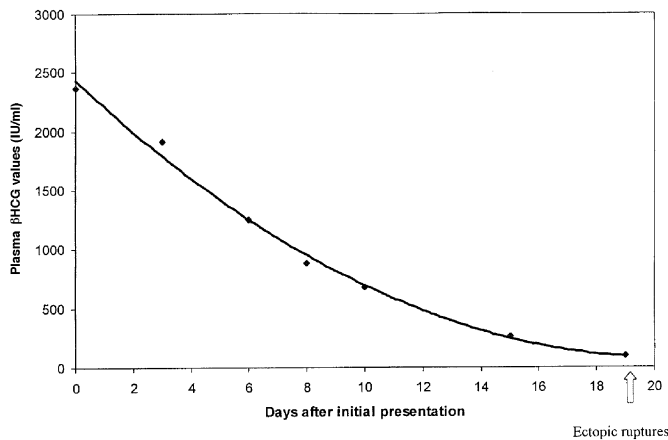


Figure 1. Serial β human chorionic gonadotrophin measurements in a 30 year old multigravid patient in whom pregnancy could not be identified by transvaginal scan.

and/or omission of quantitative serum β HCG assay with ultrasound investigation. The management of a pregnant patient who presents with vaginal bleeding and an empty uterus on ultrasound is a common problem. However, the combined use of serum quantitative β HCG assays and ultrasound can be used to aid the diagnosis of ectopic pregnancy (Kadar *et al.*, 1981). A woman with serum β HCG concentrations >1000 IU/ml can be expected to have an intrauterine sac visible on transvaginal ultrasound when an intrauterine pregnancy is present (Cacciatore *et al.*, 1988), and this knowledge can help to differentiate between an ectopic and an intrauterine pregnancy. Although the absence of a visible intrauterine pregnancy by transvaginal ultrasound scan and a serum β HCG >1000 IU/l excludes a normal pregnancy (Cacciatore *et al.*, 1990), most such pregnancies are usually incomplete miscarriage which is amenable to conservative treatment (Banerjee *et al.*, 1999). As the patient was also clinically stable and presumed to have a miscarriage, a conservative approach was therefore initially adopted. In asymptomatic pregnant women where transvaginal ultrasound is unable to identify the pregnancy, β HCG concentrations <1000 IU/l may be observed. As a result the use of early diagnostic laparoscopy has declined.

In our case report the rate of fall in serum β HCG over 19 days was consistent with a spontaneously resolving pregnancy (Sauer *et al.*, 1982), yet rupture of the ectopic pregnancy still occurred and at a serum β HCG concentration of only 97 IU/ml. In this case it was believed that the patient most likely had a spontaneous complete abortion, but her light vaginal bleed did not fit easily with this diagnosis and necessitated careful follow-up. It was planned to monitor the serum β HCG until it fell to a 'non-pregnant' value.

Serial serum β HCG measurements have previously been used to monitor ectopic pregnancies which have been managed expectantly. In a study of laparoscopically diagnosed small (<3 cm) uncomplicated ectopic pregnancy, those with a falling serum β HCG concentration were not managed expectantly. The highest serum β HCG value was 1010 IU/l, and in all cases the patients remained well with a medial resolution time of 17 days (Sauer *et al.*, 1982).

This case demonstrates the difficulties that can occur in making the diagnosis of ectopic pregnancy. The patient did not give a history of known significant risk factors such as pelvic inflammatory disease, tubal surgery, or previous ectopic pregnancy, although previous appendectomy has been implicated as a possible risk factor (Dimitry, 1987). The patient did not complain of abdominal pain (until rupture of the tube 19 days after initial presentation) and abdominal and pelvic examinations were normal when she first presented. When tubal rupture occurs leading to haemoperitoneum, symptoms and signs can develop quickly. This patient was well less than 12 h before rupture.

We believe that this case is very important in highlighting the dangers in expectant management of women where the site of the pregnancy cannot be identified. It is important to counsel women who are managed in this way of such dangers, and the need for increased vigilance and close follow-up if the serum β HCG declines to non-pregnant values.

Acknowledgements

This case report was in part funded by the Watford Gynaecological Research Fund (WGRF). We would like to thank Mrs Alison Evans for her help in the preparation of this report.

References

- Ankum, W.M., Van der Veen, F., Hamerlynch, J.V.T.H. *et al.* (1993) Laparoscopy: a dispensable tool in the diagnosis of ectopic pregnancy. *Hum. Reprod.*, **8**, 1010–1015.
- Banerjee, S., Aslam, N., Zosmer, N. *et al.* (1999) The expectant management of women with early pregnancies of unknown location. *Ultrasound. Obstet. Gynecol.*, **16**, 253–256.
- Cacciatore, B., Stenman, U.H., Ylostalo, P. *et al.* (1988) Suspected ectopic pregnancy: ultrasound findings and HCG levels assessed by an immunofluorometric assay. *Br. J. Obstet. Gynaecol.*, **95**, 497–502.
- Cacciatore, B., Stenman, U.H. and Ylostalo, P. (1989) Comparison of abdominal and vaginal sonography in suspected ectopic pregnancy. *Obstet. Gynecol.*, **73**, 770–774.
- Cacciatore, B., Stenman, U.H. and Ylostalo, P. (1990) Diagnosis of ectopic pregnancy by vaginal ultrasonography in combination with a discriminatory serum hCG level of 1000 IU/l (IRP). *Br. J. Obstet. Gynaecol.*, **97**, 904–908.
- Confidential enquiry into maternal deaths (1999) HMSO, London.
- Dimitry, E.S. (1987) Does previous appendectomy predispose to ectopic pregnancy? A retrospective case controlled study. *J. Obstet. Gynaecol.*, **7**, 221–224.
- Hahlin, M., Thorburn, J. and Bryman, I. (1995) The expectant management of early pregnancies of uncertain site. *Hum. Reprod.*, **10**, 1223–1227.
- Kadar, N. and Romero, R. (1988) Further observations on serial human chorionic gonadotrophin patterns in ectopic pregnancies and spontaneous abortions. *Fertil. Steril.*, **50**, 367–370.
- Kadar, N., Caldwell, B.V. and Romero, R. (1981) A method for screening for ectopic pregnancy and its indications. *Obstet. Gynaecol.*, **58**, 162–165.
- Lindblom, B., Hahlin, M. and Sjoblom, P. (1989) Serial human chorionic gonadotrophin determinations by fluorimmunoassay for the differentiation between intrauterine and ectopic gestation. *Am. J. Obstet. Gynecol.*, **161**, 397–400.
- Sauer, M.V., Bushills, M., Gunning, J.E. and Bulser, J.E. (1982) Non surgical management of unruptured ectopic pregnancy; an extended clinical trial. *Fertil. Steril.*, **48**, 752–755.
- Stovall, T.G. and Ling, F.W. (1993) Ectopic pregnancy. Diagnostic and therapeutic algorithms minimising surgical intervention. *J. Reprod. Med.*, **38**, 807–812.

Received on November 22, 1999; accepted on March 6, 2000